



## Interventional cholangioscopy and management of hepatic cystic echinococcosis complicated by cystobiliary fistula

Matthew R. Krafft, MD,<sup>1</sup> Paul Cassis, MD,<sup>2</sup> William Hsueh, MD,<sup>1</sup> Jeffrey M. Quedado, PharmD,<sup>3</sup> John Nasr, MD<sup>1</sup>

A 38-year-old woman, originally from Kashmir, India, presented for evaluation of right upper-quadrant abdominal pain. The results of her laboratory tests were remarkable for moderate eosinophilia (absolute eosinophil count 1760/ $\mu$ L), hyperbilirubinemia (total bilirubin 4.5 mg/dL), and elevated alkaline phosphatase (229 U/L). A CT scan of the abdomen and ultrasonography of the liver revealed a multiseptated cyst within the right hepatic lobe, measuring 10 cm  $\times$  9 cm  $\times$  9 cm (Figs. 1A and B). Additionally, dynamic US footage (not pictured) showed dense mobile echoes (“snowflake sign”), representing shifting of hydatid sand. Serologic testing detected an IgG antibody to *Echinococcus* species.

A probable case of hepatic cystic echinococcosis (World Health Organization Informal Working Group on Echinococcosis [WHO-IWGE] classification type CE2 / Gharbi classification type III [active stage]) complicated by intrabiliary rupture was diagnosed. A WHO-IWGE stage-specific approach to treatment was recommended, with use of a combined approach of antiparasitic benzimidazole (BMZ) therapy and surgery to minimize the risk of relapse.<sup>1</sup> Albendazole was begun, but the patient declined surgery despite numerous indications.

After 6 months of continuous albendazole therapy, the patient’s abdominal pain persisted, and laboratory derangements suggested an ongoing cystobiliary fistula. Repeated CT of the echinococcal cyst showed enlarged dimensions (13 cm  $\times$  12 cm  $\times$  14 cm), localized dilation of the right anteroinferior biliary tree, and degenerative morphologic alterations (ie, membrane detachment) consistent with WHO-IWGE classification type CE3a (Gharbi type II [transitional stage]). At this stage, the cyst is equally likely to be active or inactive<sup>2</sup> (Fig. 1C).

The PAIR technique (puncture, aspiration, injection [protoscolicide], reaspiration) with continuous catheter drainage and BMZ therapy was considered as a therapeutic option, given the size of the cyst and its degeneration to a nonseptate transitional stage.<sup>3,4</sup> This strategy was not used because the suspected presence of a cystobiliary fistula precluded use of the protoscolicide injection, due to the risk of chemically induced sclerosing cholangitis, and the patient declined percutaneous continuous catheter

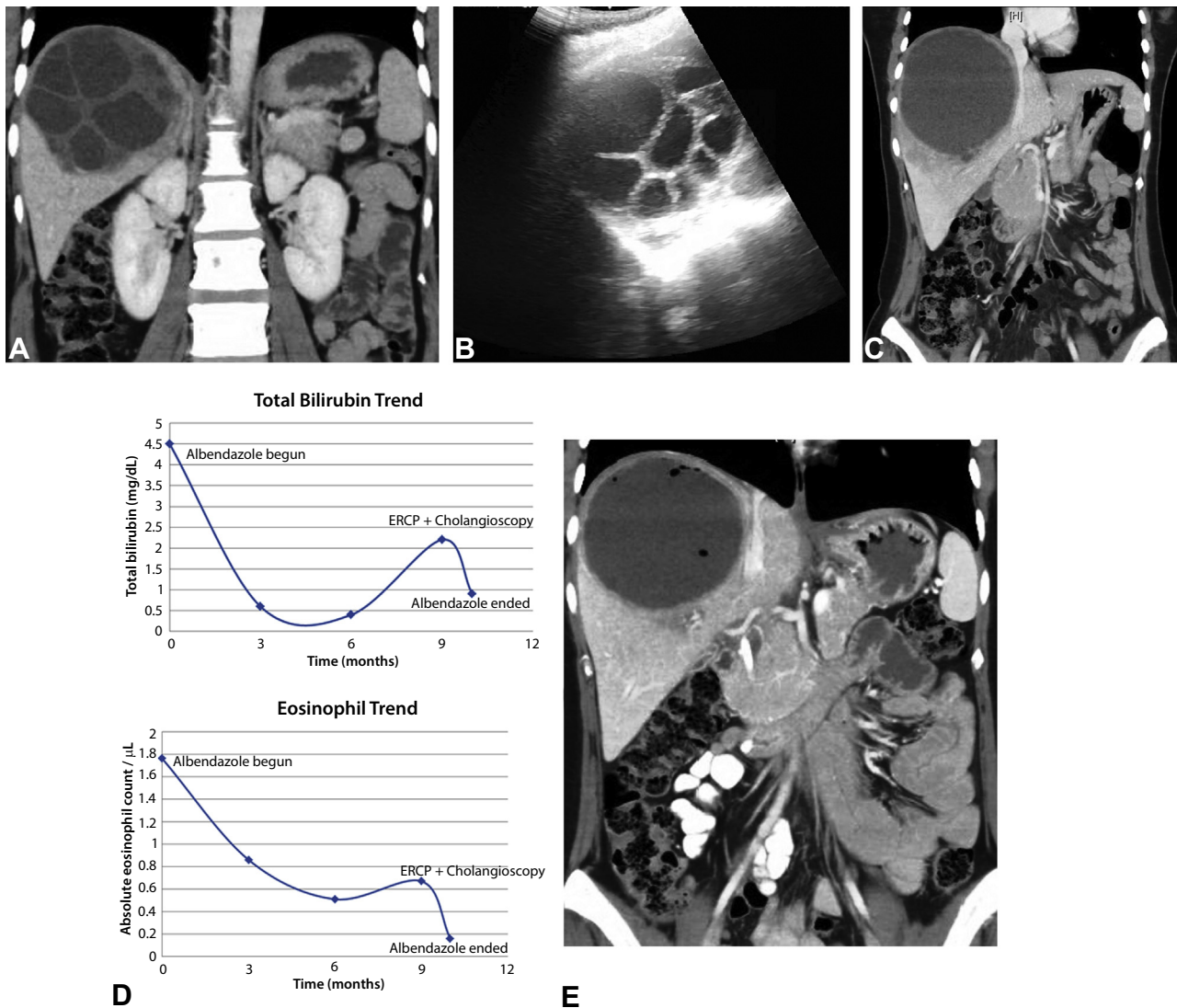
drainage.<sup>4,5</sup> To accommodate the patient’s desire for a minimally invasive approach toward management of the suspected cystobiliary fistula in the setting of a giant, nonseptate, transitional-stage echinococcal cyst, a novel therapy with ERCP and cholangiography was offered (Video 1, available online at [www.VideoGIE.org](http://www.VideoGIE.org)).

A 41.1F duodenoscope (TJF-Q180V; Olympus America, Center Valley, Pa) was inserted and advanced to the second portion of the duodenum. Bile duct cannulation was performed, and occlusion cholangiography showed contrast dye extravasating from the left and right hepatic ducts into the echinococcal cyst (Fig. 2A). Biliary endoscopic sphincterotomy, followed by sweeps of the extraction balloon catheter, expelled brood capsules and hydatid sand from the common bile duct into the duodenum (Fig. 2B). A 0.035-inch guidewire was passed through the right hepatic duct cystobiliary fistula and into the echinococcal cyst. The cholangioscope (SpyScope DS Catheter; Boston Scientific Corp, Marlborough, Mass) was passed through the duodenoscope and into the common bile duct for direct visualization. The cholangioscope was advanced along the guidewire and into the right hepatic duct, stopping immediately distal to the cystobiliary fistula.

Four hundred milliliters of 23.4% hypertonic saline solution was injected through the cystobiliary fistula to inactivate the germinal layer and to kill protoscolices remaining in the cyst cavity. Biopsy forceps (SpyBite; Boston Scientific Corp, Marlborough, Mass) were deployed through the cystobiliary fistula and into the echinococcal cyst, to mechanically disrupt the cyst contents (Fig. 2C). Newly destroyed cyst contents (eg, hydatid sand, brood capsule, and membrane fragments) were suctioned through the cystobiliary fistula by use of the cholangioscope. Extraction balloon catheter sweeps cleared residual debris from the common hepatic and bile ducts.

A 10F  $\times$  9-cm plastic stent was placed into the common bile duct to encourage biliary drainage and accelerate closure of the fistula. Biliary stent placement ensured prompt drainage of residual hypertonic saline solution, thereby decreasing the risk of chemically induced sclerosing cholangitis. No procedural adverse events occurred.

Written transcript of the video audio is available online at [www.VideoGIE.org](http://www.VideoGIE.org).



**Figure 1.** **A**, CT view with intravenous contrast material showing a giant multiseptated cyst, 10 cm  $\times$  9 cm  $\times$  9 cm. Cyst septations produce a “wheel-like” appearance. Cyst morphology is consistent with WHO-IWGE on *Echinococcus* classification type CE2 or Gharbi classification type III (active stage). **B**, Ultrasonographic view of liver showing a “rosette-like” pattern of daughter cysts contained along the inferior margin of the echinococcal cyst. **C**, CT view with intravenous contrast material demonstrating a unilocular homogenous cyst with a floating laminated membrane along the superior margin (dimensions: 13 cm  $\times$  12 cm  $\times$  14 cm). Cyst morphology is most consistent with WHO-IWGE classification type CE3a or Gharbi classification type II (transitional stage). **D**, Graph of serum absolute eosinophil count and serum total bilirubin plotted over time with markers of medical therapy and endoscopic intervention. Time 0 months represents time of diagnosis. **E**, CT view with intravenous contrast material 3 weeks after intervention with ERCP and cholangioscopy. Interim decrease in the size of the echinococcal cyst has occurred (new dimensions: 9 cm  $\times$  11 cm  $\times$  10 cm). Small foci of air are seen within the echinococcal cyst. The cyst most likely remains WHO-IWGE classification type CE3a or Gharbi classification type II (transitional stage). WHO-IWGE, World Health Organization Informal Working Group Classification.

Three weeks later, serum eosinophils, bilirubin, and alkaline phosphatase had reached normal levels (Fig. 1D). A CT scan showed decreased size of the echinococcal cyst (Fig. 1E).

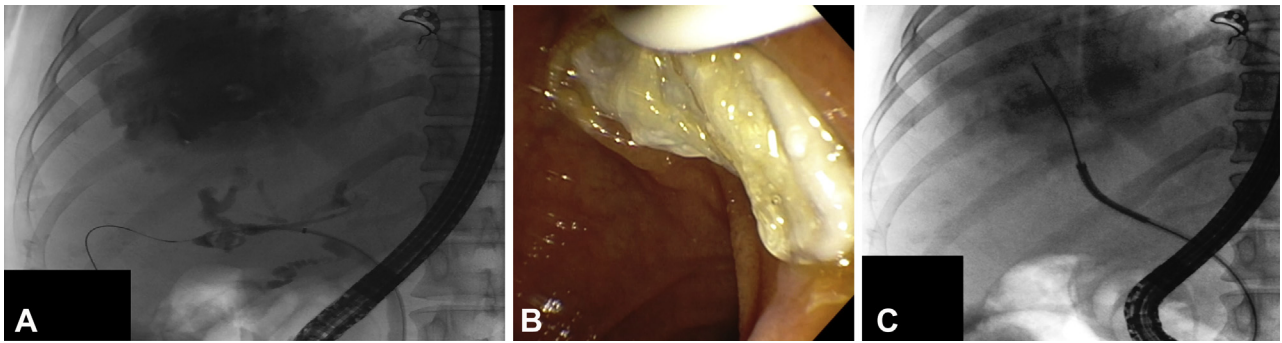
Postprocedural albendazole was continued for 1 month to decrease the risk of secondary cystic echinococcosis from protoscolex dissemination. ERCP with biliary stent removal was performed 8 weeks later, and there was no evidence of biliary tree stricturing to suggest the development of caustic sclerosing cholangitis.

**DISCLOSURE**

All authors disclosed no financial relationships relevant to this publication.

**ACKNOWLEDGMENT**

The authors thank Jon Cardinal, MD, FACS, of the Division of Surgical Oncology, West Virginia University, who worked



**Figure 2.** **A**, Occlusion cholangiogram during ERCP demonstrating cystobiliary fistulas arising from the right and left hepatic ducts. The giant echinococcal cyst is filled with contrast dye. **B**, Expulsion of brood capsules from the common bile duct, with use of extraction balloon catheter, after biliary endoscopic sphincterotomy. **C**, Fluoroscopic visualization of the biopsy forceps (SpyBite) located within the echinococcal cyst. The cholangioscope (SpyScope DS Catheter) is positioned immediately distal to the cystobiliary fistula. The biopsy forceps are being deployed across the cystobiliary fistula and into the echinococcal cyst, to mechanically disrupt the cyst contents (ie, germinal membrane, brood capsules).

closely with the authors in treating the patient, and Christine Hanks, PharmD, Department of Pharmacy, West Virginia University, who assisted with compounding the solution of 23.4% hypertonic saline solution that was instilled in the hydatid cyst.

*Abbreviations:* BMZ, benzimidazole; PAIR, puncture, aspiration, injection (protoscolicide), reaspiration; WHO-IWGE, World Health Organization Informal Working Group on Echinococcosis.

## REFERENCES

1. Brunetti E, Kern P, Vuitton DA. Writing Panel for the WHO-IWGE. Expert consensus for the diagnosis and treatment of cystic and alveolar echinococcosis in humans. *Acta Trop* 2010;114:1-16.
2. Hosch W, Junghans T, Stojkovic M, et al. Metabolic viability assessment of cystic echinococcosis using high-field 1H MRS of cyst contents. *NMR Biomed* 2008;21:734-54.
3. Khuroo MS, Dar MY, Yattoo GN, et al. Percutaneous drainage versus albendazole therapy in hepatic hydatidosis: a prospective, randomized study. *Gastroenterology* 1993;104:1452-9.
4. Men S, Yucesoy C, Edguer TR, et al. Percutaneous treatment of giant abdominal hydatid cysts: long-term results. *Surg Endosc* 2006;20:1600-6.
5. World Health Organization. Puncture, aspiration, injection, re-aspiration. An option for the treatment of cystic echinococcosis. Document WHO/CDS/CSR/APH/2001.6. Geneva: World Health Organization; 2001.

Section of Digestive Diseases (1), Department of Medicine (2), Department of Pharmacy (3), West Virginia University, Morgantown, West Virginia, USA.

Copyright © 2018 American Society for Gastrointestinal Endoscopy. Published by Elsevier Inc. This is an open access article under the CC BY-NC-ND license (<http://creativecommons.org/licenses/by-nc-nd/4.0/>).

<https://doi.org/10.1016/j.vgie.2018.02.007>