



Complete anterograde small-bowel exploration with the novel motorized spiral enteroscope

Begoña González-Suárez, MD, PhD, Antonio Giordano, MD, Miriam Escapa, RN, Josep Llach, MD, PhD

The advent of deep enteroscopy with the support of capsule endoscopy has given impetus to the diagnosis and therapy of small-bowel diseases, especially in relation to GI bleeding and Crohn's disease.¹ However, deep enteroscopy still has a few limitations, such as the

difficulty of fully exploring the small bowel and inaccurate measure of the enteroscope insertion depth.²

Motorized spiral enteroscopy (MSE) represents a novel technique for the diagnosis and treatment of small-bowel diseases. Owing to rotation of a spiral overtube mounted

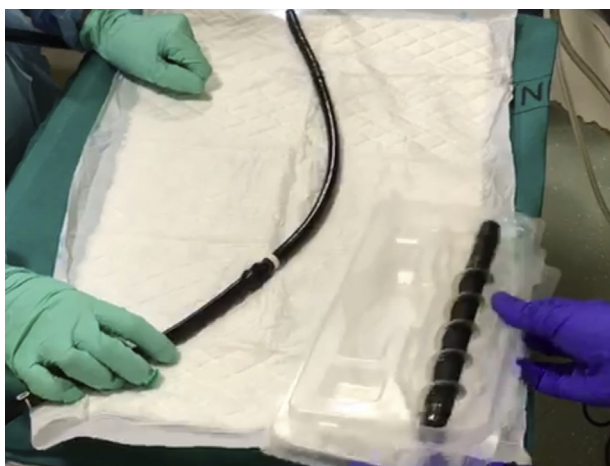

Figure 1. Enteroscope tube and spiral overtube.

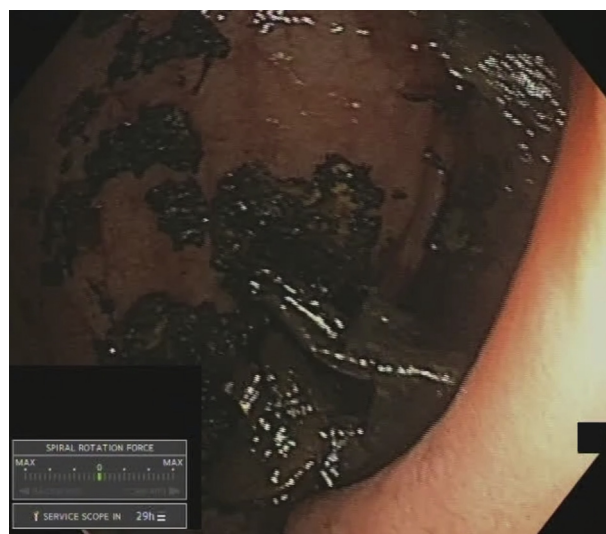

Figure 3. The tip of the enteroscope visualizes the cecum.

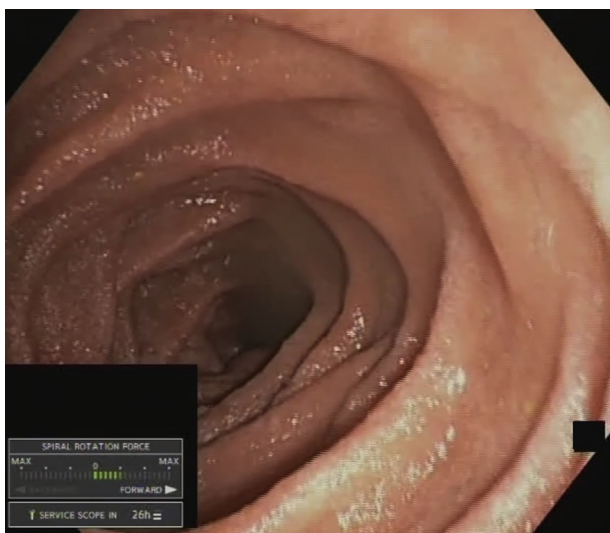


Figure 2. Small-bowel folds during advancement of the enteroscope.

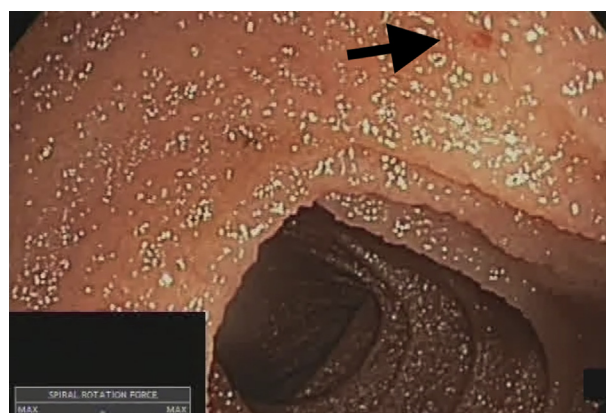

Figure 4. Diminutive angioectasia in the ileum (Type 1 b, Yano-Yamamoto Classification).

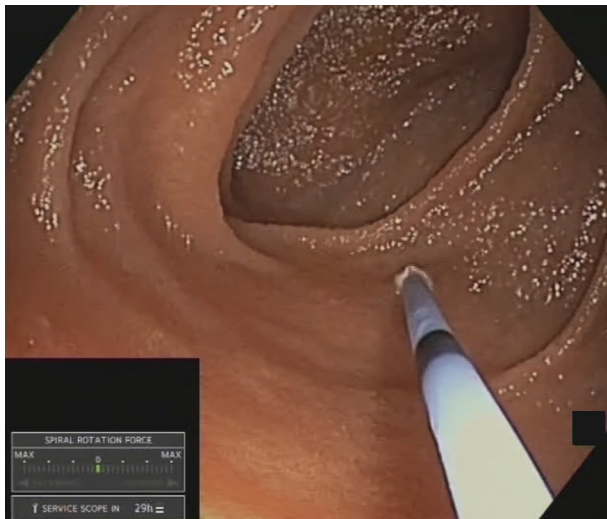


Figure 5. Use of argon plasma coagulation to treat a diminutive angioectasia.

on the enteroscope, MSE achieves rapid advancement with high insertion depth.³⁻⁵

Anterograde procedures are performed with the patient under general anesthesia, with orotracheal intubation, and after a 12-hour fast. When the retrograde route is used, deep sedation and standard bowel preparation for colonoscopy are required. An initial upper GI endoscopy is needed to exclude potential contraindications, such as strictures or narrowing of the esophageal lumen and esophageal varices. Dilation of the upper esophageal sphincter with an 18-mm Savary dilator may be performed if any resistance is noticed.

The rotating overtube pleats the bowel, allowing progression of the enteroscope tip. Generally, only slight pressure on the enteroscope is needed to facilitate its advancement. During exploration, passage through the angle of Treitz may be challenging; however, by avoiding the use of insufflation and performing a slight rectification of the enteroscope, the jejunum can be easily reached. External abdominal massage may be also performed to improve advancement through the bowel. If the overtube stops rotating because of technical issues or the detection of high resistance, a complete restart of the MSE control unit may help.

CASE REPORT

We report the case of a 48-year-old man with chronic iron-deficiency anemia who had undergone previous capsule endoscopy that revealed a few angioectasias in the jejunum and ileum (Video 1, available online at www.VideoGIE.org). Anterograde MSE was scheduled to treat the vascular lesions. No esophageal strictures or narrowing were observed during upper GI endoscopy,

and no dilation of the upper esophageal sphincter was required.

Before starting the procedure, the spiral enteroscope was adequately lubricated (Fig. 1). Subsequently, the tube was introduced through the mouth and advanced through the esophagus and stomach. Finally, the enteroscope tip reached the small bowel, passing beyond the angle of Treitz (Fig. 2). During the exploration, abdominal massage was performed to aid endoscope advancement. In this clinical case, in less than an hour, the tip of the enteroscope reached the cecum (Fig. 3). The enteroscope then was slowly withdrawn while treating previously detected small vascular lesions (type 1b Yano-Yamamoto Classification) (Figs. 4 and 5). Biopsy specimens of jejunal mucosa with mild edema and villous blunting were also taken. No signs of trauma were observed during withdrawal. No adverse events were detected.

The novel MSE may perform a complete exploration of the small bowel, including therapeutic procedures, in a short period of time.

DISCLOSURE

Dr. González-Suárez received lecture fees from Olympus Medical Systems; Olympus Medical provided the endoscopic equipment. All other authors disclosed no financial relationships relevant to this publication.

Abbreviation: MSE, motorized spiral enteroscopy.

REFERENCES

1. Pennazio M, Spada C, Eliakim R, et al. Small-bowel capsule endoscopy and device-assisted enteroscopy for diagnosis and treatment of small-bowel disorders: European Society of Gastrointestinal Endoscopy (ESGE) Clinical Guideline. *Endoscopy* 2015;47:352-76.
2. Seong RJ, Jin-Oh K. Deep enteroscopy: which technique will survive? *Clin Endosc* 2013;46:480-5.
3. Giordano A, Pino YVD, Escapa M, et al. Preliminary experience with the novel motorized spiral enteroscope (Powerspiral) for small bowel diseases. *Endoscopy* 2020;52:S46.
4. Beyna T, Arvanitakis M, Schneider M, et al. Motorised spiral enteroscopy: first prospective clinical feasibility study. *Gut* 2020 Apr 24.
5. Mans L, Arvanitakis M, Neuhaus H, et al. Motorized spiral enteroscopy for occult bleeding. *Dig Dis* 2018;36:325-7.

Endoscopy Unit, Gastroenterology Department, Hospital Clinic of Barcelona, Barcelona, Spain.

Copyright © 2020 American Society for Gastrointestinal Endoscopy. Published by Elsevier Inc. This is an open access article under the CC BY-NC-ND license (<http://creativecommons.org/licenses/by-nc-nd/4.0/>).

<https://doi.org/10.1016/j.vgie.2020.05.035>