

Endoscopic revision for weight regain after open vertical-banded gastroplasty



Salvatore F. Vadalà di Prampero, MD, PhD, FASGE,¹ Milutin Bulajic, MD, PhD, FACG, FASGE,¹
Piero Giustacchini, MD,^{2,3} Gabriella Manzoni, MD,⁴ Guido Costamagna, MD, FACG, FASGE⁵

Vertical-banded gastroplasty (VBG) was one of the most popular restrictive bariatric procedures in the 1980s and 1990s, with excellent short- and medium-term results.^{1,2} Mason described the open VBG (OVBG) for the first time in 1982,³ consisting of the application of staples from above the gastric crow's foot up to the angle of His to create a tiny pouch (<50 mL), together with the construction of a neopylorus with a polypropylene mesh collar (Fig. 1). The procedure was modified and performed laparoscopically (laparoscopic vertical-banded gastroplasty) by MacLean in 1993.⁴

Despite satisfactory initial outcomes, problems gradually started to appear, mainly with the OVBG. A high number of patients had either gastric outlet obstruction adverse events or weight regain⁵⁻⁹ because of staple-line dehiscence (gastrogastric fistula) and subsequent gastric pouch enlargement. This occurred in up to 65% of patients in the long term.^{5,10}

Traditionally, weight regain after VBG is treated with surgical conversion to Roux-en-Y gastric bypass (RYGB).¹¹⁻¹⁸ This conversion may be extremely challenging and time-consuming (~200 minutes) and has been associated with higher early morbidity (anastomotic leakage, intra-abdominal abscess, internal hernia, wound abscess and

infection, urinary tract infection, pneumonia) and long-term morbidity (anastomotic stenosis and incisional hernia; up to 39%) than primary RYGB.^{11,15} However, to our knowledge, there has been no published report of endoscopic therapy for weight regain after VBG.

In this video (Video 1, available online at www.VideoGIE.org) we illustrate the safety, technical feasibility, and efficacy of a new endoscopic technique to treat weight regain after OVBG using an endoscopic suturing device.

Our patient was a 51-year-old woman with a history of OVBG in 2004 who presented with weight regain. Her pre-OVBG weight was 98 kg, with a postsurgical nadir weight of 58 kg. Her weight at presentation was 103.3 kg, representing a regain of 78.1% of her maximal weight loss and a body mass index of 40.1 kg/m². She was adherent to lifestyle interventions and finally tried a low-carbohydrate diet without losing weight. The patient refused to undergo conversion of VBG to RYGB; therefore, she was referred to the bariatric endoscopy clinic. Diagnostic endoscopy revealed a dilated gastric pouch with staple-line dehiscence (Figs. 2 and 3).

The endoscopic suturing system described in this video consists of Overstitch Sx (Apollo Endosurgery, Austin, Tex, USA), an over-the-scope single-channel suturing device

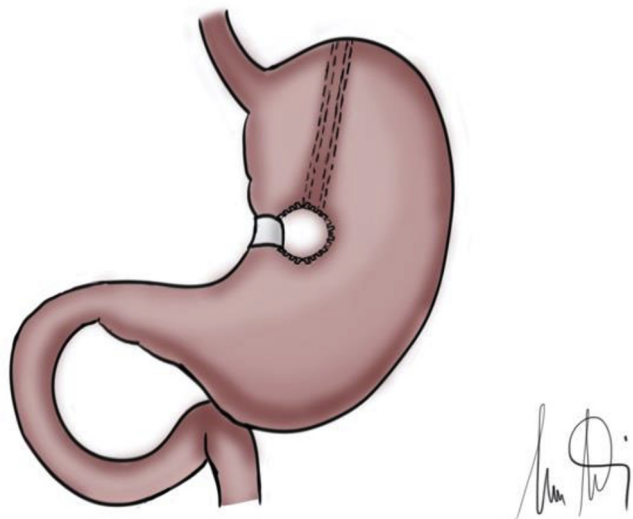


Figure 1. Illustration of Mason's open vertical banded gastroplasty.

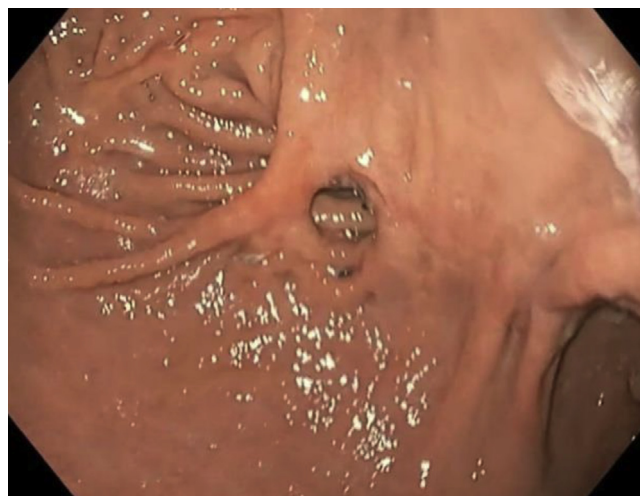

Figure 2. The dilated gastric pouch with a staple-line dehiscence (top left) with a mucosal bridge and the distal part of the staple-line, close to the gastric outlet (lower right), still undisrupted.

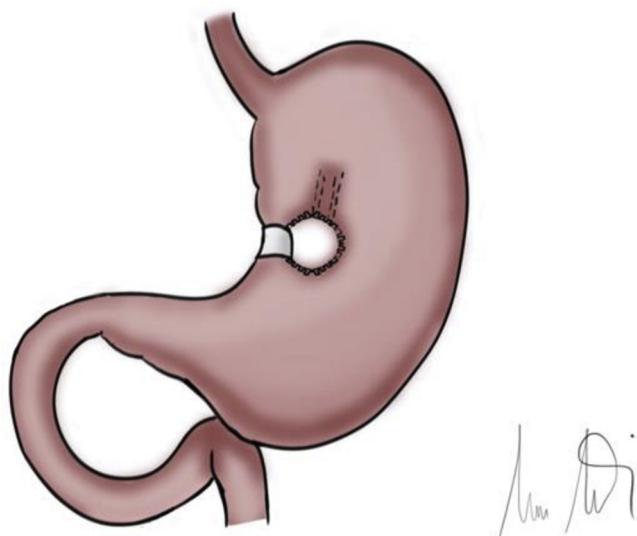


Figure 3. Illustration of staple-line dehiscence.




Figure 4. Endoscopic suturing device.

with a catheter-type tissue screw or tissue helix to ensure sequential full-thickness bites (Fig. 4). This device has been used for primary endoscopic bariatric therapy, revision of RYGB, and endoscopic sleeve gastroplasty but to our knowledge has not yet been reported for revision of VBG.

The procedure described in this video is characterized as a suturing procedure along the staple-line disruption with a focus on recreating the original gastric pouch. First, a full-thickness bite is taken in the retroflexed position on the residual greater curvature of the proximal body, just 3 cm below the G-E junction, along 1 of the 2 borders of the proximal staple-line dehiscence; then a second bite is taken on the opposite side of the staple-line dehiscence just 1 cm below the previous one. In this way, a running suture is performed following a top-down “Z” pattern placing 5 stitches and finally approaching the opposite sides of the staple-line disruption with a suture cinch. A second distal suture with 2 full-thickness bites following

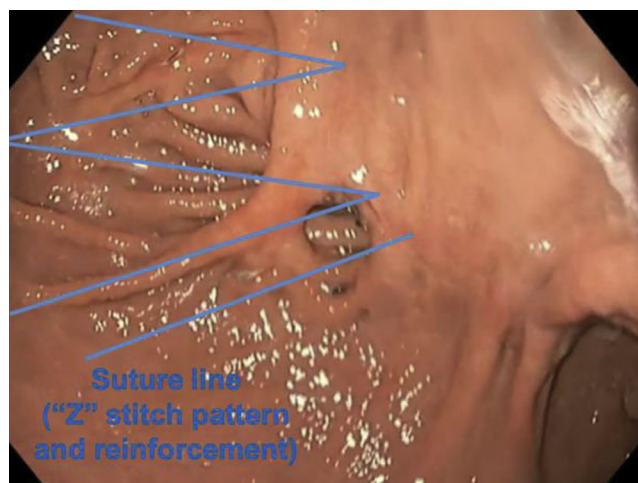

Figure 5. Running sutures with a “Z” stitch pattern and a reinforcement.

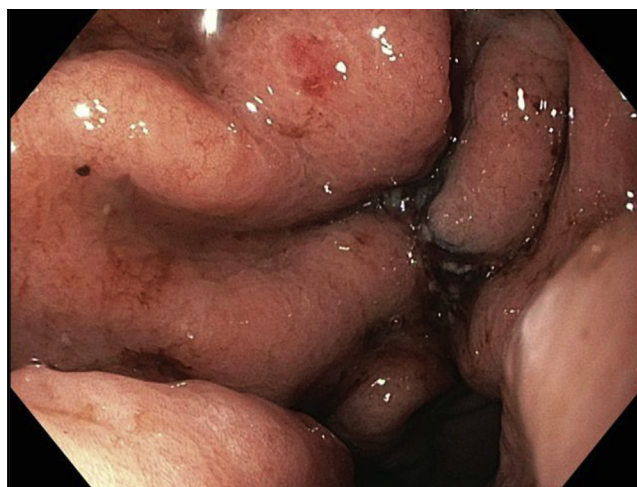

Figure 6. Final result: opposite sides of staple-line dehiscence approached, with restoration of the original tiny gastric pouch.

the previous pattern is performed to reinforce the first suture and further reduce the residual gastric pouch (Figs. 5 and 6).

The procedure time was 28 minutes. No intra-procedural or early adverse events were encountered, and the patient was discharged the next day. She was prescribed a proton pump inhibitor and was maintained on a liquid diet for 5 days. At 1 and 3 months, her weight had decreased from 103.3 kg to 94.9 kg and 89.4 kg, corresponding to an 8.1% and 13.5% total weight loss and a 22% and 36.7% excess weight loss, respectively.

In conclusion, in this video, we present a case of safe and effective endoscopic treatment of weight regain after OVBG using a novel suturing technique in which the single-channel overstitch suturing system, rather than the double-channel suturing system, was used to maximize

endoscope retroflexion; this is fundamental in this intervention and easier to reach with the single channel device.

Given the past high prevalence of OVBG, gastroenterologists will continue to see a certain number of these patients. Further study to better define patient selection criteria and long-term outcomes is needed.

DISCLOSURE

Dr Costamagna is a consultant for Boston Scientific, Cook Medical, and Olympus Medical. All other authors disclosed no financial relationships.

Abbreviations: OVBG, open vertical-banded gastroplasty; RYGB, Roux-en-Y gastric bypass; VBG, vertical-banded gastroplasty.

ACKNOWLEDGMENTS

We thank Dr A. Agnes, Dr P. Bazzu, Dr S. Masia, Dr V. Milano, Dr D. Pagliara, and Dr P. Rinaldi for their contribution as members of Mater Olbia Hospital bariatric team. We thank Mr M. Diamanti for his contribution to the drawings.

REFERENCES

- van Hout GC, Jakimowicz JJ, Fortuin FA, et al. Weight loss and eating behavior following vertical banded gastroplasty. *Obes Surg* 2007;17:1226-34.
- Bekheit M, Katri K, Salam WN, et al. Rejecting the demise of vertical-banded gastroplasty: a long-term single-institute experience. *Obes Surg* 2013;23:1604-10.
- Mason EE. Vertical banded gastroplasty for obesity. *Arch Surg* 1982;117:701-6.
- MacLean LD, Rhode BM, Forse RA. A gastroplasty that avoids stapling in continuity. *Surgery* 1993;113:380-8.
- Marsk R, Jonas E, Gartzios H, et al. High revision rates after laparoscopic vertical banded gastroplasty. *Surg Obes Relat Dis* 2009;5:94-8.
- Balsiger BM, Poggio JL, Mai J, et al. Ten and more years after vertical banded gastroplasty as primary operation for morbid obesity. *J Gastrointest Surg* 2000;4:598-605.
- Mason EE, Cullen JJ. Management of complications in vertical banded gastroplasty. *Curr Surg* 2003;60:33-7.
- del Amo DA, Diez MM, Guedea ME, et al. Vertical banded gastroplasty: is it a durable operation for morbid obesity? *Obes Surg* 2004;14:536-8.
- van Wezenbeek MR, Smulders JF, de Zoete JPJM, et al. Long-term results of primary vertical banded gastroplasty. *Obes Surg* 2015;25:1425-30.
- Schouten R, Wiryasaputra DC, van Dielen FM, et al. Long-term results of bariatric restrictive procedures: a prospective study. *Obes Surg* 2010;20:1617-26.
- Sanchez H, Cabrera A, Cabrera K, et al. Laparoscopic Roux-en-Y gastric bypass as a revision procedure after restrictive bariatric surgery. *Obes Surg* 2008;18:1539-43.
- Apers JA, Wens C, van Vloderp V, et al. Perioperative outcomes of revisional laparoscopic gastric bypass after failed adjustable gastric banding and after vertical banded gastroplasty: experience with 107 cases and subgroup analysis. *Surg Endosc* 2013;27:558-64.
- Gonzalez R, Gallagher SF, Haines K, et al. Operative technique for converting a failed vertical banded gastroplasty to Roux-en-Y gastric bypass. *J Am Coll Surg* 2005;201:366-74.
- David MB, Abu-Gazala S, Sadot E, et al. Laparoscopic conversion of failed vertical banded gastroplasty to Roux-en-Y gastric bypass or biliopancreatic diversion. *Surg Obes Relat Dis* 2015;11:1085-91.
- Schouten R, van Dielen FM, van Gemert WG, et al. Conversion of vertical banded gastroplasty to Roux-en-Y gastric bypass results in restoration of the positive effect on weight loss and co-morbidities: evaluation of 101 patients. *Obes Surg* 2007;17:622-30.
- Cariani S, Agostinelli L, Leuratti L, et al. Bariatric revisionary surgery for failed or complicated vertical banded gastroplasty (VBG): comparison of VBG reoperation (re-VBG) versus Roux-en-Y gastric bypass-on-VBG (RYGB-on-VBG). *J Obes* 2010;2010:206249.
- Suter M, Ralea S, Millo P, et al. Laparoscopic Roux-en-Y gastric bypass after failed vertical banded gastroplasty: a multicenter experience with 203 patients. *Obes Surg* 2012;22:1554-61.
- Khewater T, Yercovich N, Grymonprez E, et al. Twelve-year experience with Roux-en-Y gastric bypass as a conversional procedure for vertical banded gastroplasty: are we on the right track? *Obes Surg* 2019;29:3527-35.

Gastroenterology and GI Endoscopy Unit, Mater Olbia Hospital, Qatar Foundation Endowment & Gemelli Foundation, Olbia, Italy (1), Endocrine and Metabolic Surgery Unit, Mater Olbia Hospital, Qatar Foundation Endowment & Gemelli Foundation, Olbia, Italy (2), Division of Endocrine and Metabolic Surgery, Fondazione Policlinico A. Gemelli IRCCS, Università Cattolica del Sacro Cuore, Rome, Italy (3), Department of Radiology, Mater Olbia Hospital, Qatar Foundation Endowment & Gemelli Foundation, Olbia, Italy (4), Digestive Endoscopy Unit, Università Cattolica del Sacro Cuore, Rome, Italy (5).

If you would like to chat with an author of this article, you may contact Dr Vadalà di Prampero at salvatore.vadala@materolbia.com.

Copyright © 2021 American Society for Gastrointestinal Endoscopy. Published by Elsevier Inc. This is an open access article under the CC BY-NC-ND license (<http://creativecommons.org/licenses/by-nc-nd/4.0/>).

<https://doi.org/10.1016/j.vgie.2021.05.017>