

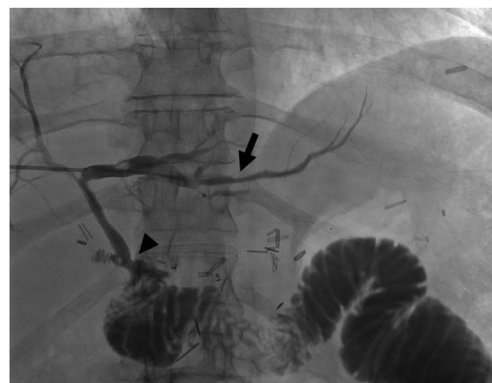


## With a little help from my friends: percutaneously assisted internalization of a biliary drain

Jad AbiMansour, MD,<sup>1</sup> Chad Fleming, MD,<sup>2</sup> Eric J. Vargas, MD,<sup>3</sup> Ryan Law, DO<sup>3</sup>

### BACKGROUND

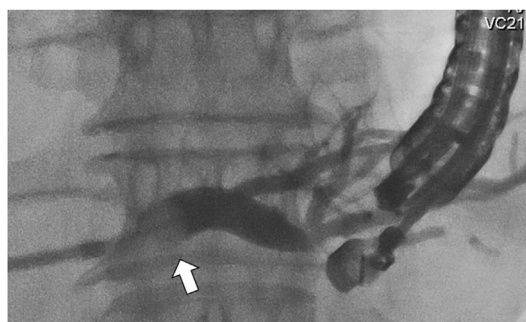
EUS-guided hepaticogastrostomy (EUS-HG) provides endoscopic biliary drainage when conventional techniques are not feasible.<sup>1</sup> While comparable to percutaneous transhepatic drainage in regard to safety and efficacy,<sup>2</sup> endoscopic drainage forgoes the need for cumbersome external drain hardware and promotes physiologic enterohepatic circulation of bile.<sup>3</sup> In the absence of biliary dilation, the procedure can be technically challenging because access to the biliary tree is commonly obtained transgastrostomically with EUS-guided puncture of the left intrahepatic ducts. Here, we present the use of a preexisting percutaneous transhepatic biliary drain (PTBD) tract to distend the left-sided biliary tree and facilitate the completion of EUS-HG (Video 1, available online at [www.giejournal.org](http://www.giejournal.org)).



**Figure 1.** Cholangiogram obtained through a percutaneous transhepatic biliary drain highlighting diffuse intrahepatic strictures (*arrow*), a relatively patent hepaticojejunostomy, and contrast pooling in the biliary limb.

### CASE

A 43-year-old woman with a history of total pancreatectomy for chronic pancreatitis followed by surgical revision, which included a Roux-en-Y reconstruction and hepaticojejunostomy (HJ), presented for a second opinion regarding recurrent episodes of cholangitis despite a relatively patent HJ. There was significant concern for biliary limb dysmotility, and she initially underwent surgical revision of the jejunojunostomy with limited improvement. She continued to have issues with cholangitis, prompting placement of a PTBD. Cholangiography through the drain confirmed diffuse, intrahepatic stricturing (Fig. 1, *arrow*) and a patent HG (Fig. 1, *arrowhead*). Her course was subsequently



**Figure 2.** A balloon occlusion catheter passed through the existing percutaneous drain tract with the balloon insufflated (*arrow*) and contrast injected to opacify and distend the left intrahepatic duct.

Abbreviations: HG, hepaticogastrostomy; HJ, hepaticojejunostomy; PTBD, percutaneous transhepatic biliary drain.

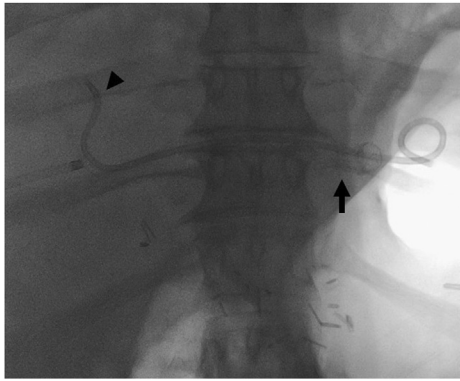
Copyright © 2023 American Society for Gastrointestinal Endoscopy. Published by Elsevier Inc. This is an open access article under the CC BY-NC-ND license (<http://creativecommons.org/licenses/by-nc-nd/4.0/>). 2468-4481

<https://doi.org/10.1016/j.vgie.2022.10.010>

Division of Gastroenterology and Hepatology, Mayo Clinic, Rochester, Minnesota (1), Division of Vascular and Interventional Radiology, Mayo Clinic, Rochester, Minnesota (2), Division of Gastroenterology and Hepatology, Mayo Clinic, Rochester, Minnesota (3).

complicated by high biliary drain output, which exceeded 1 to 2 L per day. This resulted in frequent hospitalizations for dehydration as well as progressive fat-soluble vitamin deficiency despite aggressive supplementation. After a multidisciplinary discussion involving surgery, interventional radiology, and gastroenterology, it was felt that internalizing drainage would help address these issues by promoting a more physiologic flow of bile.

The procedure was performed with the patient under general anesthesia, and the patient was given a dose of peri-operative piperacillin-tazobactam. The PTBD was first exchanged over a wire to a sheath and balloon catheter.



**Figure 3.** Final fluoroscopic imaging showing the fully covered metal stent traversing the hepaticogastrostomy (*arrow*) and plastic double pigtail stent draining the right side of the biliary tree (*arrowhead*).

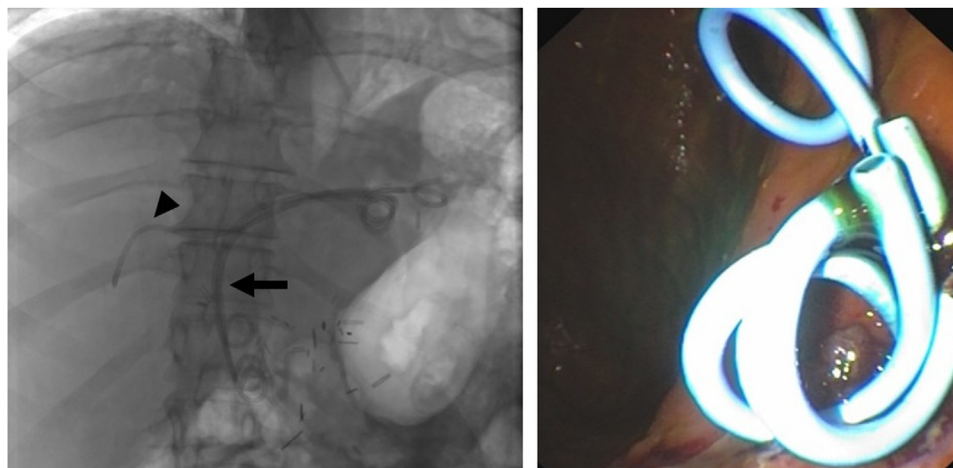
Under fluoroscopic guidance, the percutaneous balloon catheter was advanced into the left hepatic duct, the balloon inflated (*Fig. 2, arrow*), and contrast injected to opacify and distend the target ducts (*Fig. 2*). A branch of the left hepatic duct was then punctured under EUS-guidance with a 19-gauge needle followed by advancement of a 0.025-inch angled guidewire across the HJ. After dilating the tract with a 4-mm balloon, a 10-mm × 8-cm fully covered self-expandable metal stent was deployed with the distal end in the left hepatic duct and proximal end in the stomach (*Fig. 3, arrow*). A guidewire was then used to access the right hepatic duct, and a plastic double-pigtail catheter was deployed across the HG (*Fig. 3, arrowhead*). The patient did well postprocedurally with no additional hospitalizations for cholangitis and improvement in nutrition parameters.

Routine stent exchange was performed at 8 weeks, at which time all stents were removed and exchanged for plastic stents, including 3 traversing the HJ (*Fig. 4, arrow*)

and 1 in the right posterior hepatic duct (*Fig. 4, arrowhead*). The metal stent was replaced with plastic stents as destination therapy to minimize any risk of erosion, migration, and bleeding. It is our experience that the plastic stents help with tissue apposition and formation of the hepaticogastrostomy while minimizing mucosal injury when the gastric lumen collapses. These stents would likely need to be exchanged every 6 to 12 months indefinitely to prevent cholangitis, which is a limitation to this approach, but was discussed with the patient and felt to be much more advantageous than repeated hospitalizations. It also allowed for physiologic bile flow and improved nutrient absorption. Multiple stents were used given the size of the ducts and to maintain patency for extended periods of time. In theory, multiple stents also provide for continued drainage if one stent were to become occluded. The patient did well postprocedurally with no additional hospitalizations for cholangitis and improvement in nutrition parameters. She continues to follow up with local providers for routine stent exchanges.

## DISCUSSION

EUS-guided biliary drainage is safe and effective when performed by experienced endosonographers.<sup>4,5</sup> Visualization of the intrahepatic ducts is critical, and the procedure can be technically demanding in patients without dilated ducts. Here we report a creative approach to the procedure, which unencumbered the patient from external hardware and improved her nutrition through internalizing biliary drainage. The case also highlights the importance of careful patient selection and using a multidisciplinary, collaborative approach to maximize the likelihood of a successful outcome.



**Figure 4.** Routine stent exchange performed at 8 weeks with removal of initial stents and placement of 4 pigtails, 3 traversing the hepaticojejunostomy (*arrow*) and one in the right posterior hepatic duct (*arrowhead*).

## DISCLOSURE

*Dr Law is a consultant for ConMed and Boston Scientific and receives royalties from UpToDate. All other authors disclosed no financial relationships.*

## REFERENCES

1. Liao WC, Angsuwatcharakon P, Isayama H, et al. International consensus recommendations for difficult biliary access. *Gastrointest Endosc* 2017;85:295-304.
2. Artifon ELA, Aparicio D, Paione JB, et al. Biliary drainage in patients with unresectable, malignant obstruction where ERCP fails: endoscopic ultrasonography-guided choledochoduodenostomy versus percutaneous drainage. *J Clin Gastroenterol* 2012;46:768-74.
3. Roberts MS, Magnusson BM, Burczynski FJ, et al. Enterohepatic circulation. *Clin Pharmacokinet* 2002;41:751-90.
4. Dhir V, Itoi T, Khashab MA, et al. Multicenter comparative evaluation of endoscopic placement of expandable metal stents for malignant distal common bile duct obstruction by ERCP or EUS-guided approach. *Gastrointest Endosc* 2015;81:913-23.
5. Vila JJ, Pérez-Miranda M, Vazquez-Sequeiros E, et al. Initial experience with EUS-guided cholangiopancreatography for biliary and pancreatic duct drainage: a Spanish national survey. *Gastrointest Endosc* 2012;76:1133-41.

### Twitter

Become a follower of *VideoGIE* on Twitter. Learn when new articles are posted and receive up-to-the-minute news as well as links to our latest videos. Search @VideoGIE on Twitter.